

## ORIGINAL PAPER

# Treatment of psoriatic skin lesions with a new Er:Yag laser technology: A case series study

Natalia G. Kalashnikova<sup>1</sup> | Torello Lotti<sup>2</sup>  | Diana S. Urakova<sup>3</sup> |  
Mohammad Jafferany<sup>4</sup> 

<sup>1</sup>Department of Dermatology, Linline Clinic Chain, Moscow, Russia

<sup>2</sup>Dermatology and Venereology, Guglielmo Marconi University, Rome, Italy

<sup>3</sup>Department of Dermatology, Institute of Medical and Social Technologies, Moscow, Russia

<sup>4</sup>College of Medicine, Central Michigan University, Saginaw, Michigan

**Correspondence**

Mohammad Jafferany, College of Medicine, Central Michigan University, Saginaw, Michigan.

Email: mjafferany@yahoo.com

**Abstract**

Erbium: YAG (Er:YAG) laser with RecoSMA technology. This laser emits thousands of microbeams of energy causing superficial epidermal ablation and a separation of dermal fibers due to a mechanical-acoustic and resonance effect. The aim of this study is to evaluate the clinical efficacy of Erbium: YAG (Er:YAG) laser with RecoSMA in the treatment of stable psoriasis vulgaris lesions. A questionnaire completed by 112 patients enrolled in the study. Photographs taken before each session, the analysis of the dynamics index PASI and histological studies were analyzed to visually monitor the clinical progress. The analyses were carried out with the help of computer software. The results after treatment of average number of sessions per course showed the complete clinical remission of the skin lesions in over 87% of the patients treated. The Er:YAG laser and RecoSMA have demonstrated the high effectiveness of the laser method of treating skin manifestations of the disease and improving the quality of life of patients.

**KEYWORDS**

psoriasis vulgaris, PASI index, space-modulated ablation, RecoSMA technology, laser, Er:YAG, mechanical-acoustic effect

## 1 | INTRODUCTION

Psoriasis is one of the most common skin diseases. It affects 2–7% of the world's population, (Drew, 2000; Lowes, Bowcock, & Krueger, 2007; Rapp, Feldman, Exum, Fleischer Jr, & Reboussin, 1999). The disease leads to a decrease in the quality of life, and has significant psychosocial percussion. (Finlay, 2015; Griffiths & Barker, 2007; Lowes et al., 2007; Richards, Fortune, Weidmann, Sweeney, & Griffiths, 2004).

Psoriasis is a systemic disease with dominant manifestations on the skin. Local treatment is prescribed for most cases of skin lesions, and it is one of the main components used in the comprehensive therapeutic treatment of this disease (Griffiths & Barker, 2007; Richards et al., 2004). It is also necessary to note the presence of adverse side effects, including those of a systemic nature, as well as the wide range of contraindications to the use of most methods and drugs for the local treatment of this disease. The treatment time must be shortened,

and it must be easy for patients to comply with the doctor's regime and recommendations without significantly limiting their lifestyle (Damevska, França, Lotti, Nikolovska, & Pollozhani, 2018).

Light was one of the first therapeutic physical factors that was used to treat skin manifestations of psoriasis. Phototherapy with UV radiation was first practiced in 1925, and it still remains one of the standard treatments. With increasing interest in and research into the use of medical lasers, however, these new methods are expanding the options for the treatment of psoriasis (Zhang & Wu, 2017).

Laser therapy was first used to treat manifestations of psoriasis in 1986 to remove psoriatic plaques by ablation with a carbon dioxide (Bekassy & Astedt, 1986). These lasers affected the epidermis and the papillary dermis, which led to the elimination of the rash while achieving the reverse Koebner's phenomenon. However, the use of this method was limited by the trauma inflicted by the procedure and a wound epithelialization period of between 2 and 6 weeks. Therefore,

the laser procedure was only recommended in cases where patients had slowly and stably progressing small plaques and only if local treatment first failed to be effective (Alora, Anderson, Quinn, & Taylor, 1998).

The development of methods based on the fractional principle of exposure has made it possible to reduce the amount of trauma caused by ablation and the risk of side effects, shortening the recovery period, and making the course of treatment easier for the patient. These factors have provided the basis for expanding the indications for the use of laser methods in aesthetic medicine.

The objective of this prospective study was to analyze the response of plaques of psoriasis to an Er:YAG 2,940 nm laser equipped with a new optical system for energy deposition in tissues. (Multyline Belorussian, Linline Company) RecoSMA technology is based on a sophisticated optical technology which produces shallow ablation of the epidermis and a resonance effect in the dermis. A combined mechanical and acoustic double-action effect enables the removal of pathological tissues on the surface and stimulates the restoration of the normal structure of the skin in plaque psoriasis (the reverse Koebner phenomenon—the resolution of the pathological focus after damage).

The study was conducted between October 2013 and December 2015 at the Linline network of clinics. The follow-up period is 4 years, which still continues to this day. We established the length of the period with a view of determining the maximum period of remission.

## 2 | MATERIALS AND METHODS

### 2.1 | Patient inclusion and exclusion criteria

Patients are selected for SMA method treatment on the basis of the same principles that are used for other laser and phototherapy methods of treating psoriasis: the main indication is symptoms of psoriasis vulgaris or inverse psoriasis that have been developing stably. Laser and photo treatment is not recommended for widespread and unstable psoriasis vulgaris or for drop-shaped, pustular, or erythrodermic psoriasis (Zhang & Wu, 2017).

The study was approved by the Ethical Committee of the Linline network of clinics and was in accordance with the Declaration of Helsinki.

### 2.2 | Inclusion criteria for the study

- The informed consent form to participate in the study and to grant the use of information and photo documents for scientific purposes (in accordance with GCP requirements—Good Clinical Practice) signed after being explained in detail about the nature of the study, the protocol and the purpose of the treatment.
- Patient age: between 20 and 60.
- Established diagnosis: psoriasis vulgaris.
- Stationary stage psoriasis.

- Mild and moderately severe symptoms (PASI index of up to 10 points, DLQI index of up to 10 points).
- Clinical findings that the disease is progressing slowly and stably; this progression has not been significantly changed by the application of topical therapies.
- Absence of complications from secondary infections.

### 2.3 | Criteria for the exclusion of patients from the study

- Presence of general contraindications to laser therapy.
- Medical history of photoallergic reactions.
- Completion of a course of immunosuppressive or cytostatic therapies less than 3 months before the start of treatment
- Patients who did not respect the study protocol

### 2.4 | Sample of patients

One hundred and fifteen patients signed up for the study and one hundred and twelve completed it. Three patients dropped out in connection with the aggravation of comorbidity, and the impossibility of adherence to the study protocol. The mean age of the study group of 112 patients (61 women and 51 men) was  $35.3 \pm 3.7$  years ( $r = 24-60$ ). All patients met the selection criteria. The duration of the disease varied from 2 to 32 years, with an average of  $8.1 \pm 1.2$  years.

In order to clinically assess the patients' condition, the widely used Psoriasis Area and Severity Index (PASI) and Dermatological Life Quality Index (DLQI) were calculated. The PASI indexes reported by members of study group was in the range of 5–10, with an average of  $8.4 \pm 0.41$  points. The DLQI indicator before treatment for patients in the study group varied from 6 to 10 points and averaged  $7.9 \pm 0.43$  points.

### 2.5 | Treatment

The treatment was carried out using the Er:YAG laser (2940 nm) with the treatment head SMA (space-modulated ablation)—RecoSMA technology.

The treatment program consisted of a series of laser sessions RecoSMA technology with a 3–4 weeks interval between them. One pass of the laser were made with a superposition of pulses of ~30%, covering all psoriatic plaques and the surrounding tissue at a distance 0.5 cm.

In each treatment session a dose of energy was selected individually with a frequency of 3 Hz. An important condition for realization of reverse Koebner's phenomenon is ensuring sufficient depth of impact, which must penetrate into the dermis. The depth of influence with RecoSMA depends on the dose of energy (at a constant duration of the laser pulse). The thickness of the epidermis of psoriatic plaques is determined by the degree of desquamation. Obviously, the dose of

energy would be correlated with the degree of desquamation. The higher the degree of desquamation, the greater the dose of energy used:

- Degree 0: dose of 2.21 J/cm<sup>2</sup>
- Degree 1: dose of 2.54 J/cm<sup>2</sup>
- Degree 2: dose of 2.9 J/cm<sup>2</sup>
- Degree 3: dose of 3.2 J/cm<sup>2</sup>
- Degree 4: dose of 3.4 J/cm<sup>2</sup>


In recovery period patients were advised not to wet the affected area for 1 day, to apply Bepanthen or Avene cream to the treated area two times a day for 7 days (with the exception of the scalp), and to not take any other medications during this period.

The course of therapy was continued until the achievement of complete clinical remission or stabilization of the PASI without further dynamics.

The follow-up period continues to that time with the purpose of establishing the maximum period of remission. Currently, 14 patients are follow-up from the study group, the other patients dropped out for various reasons.

## 2.6 | Laser system and RecoSMA technology

The RecoSMA technology uses microablation, and it is based on the interferential principle of sound waves that inflict microtrauma on cells. It is performed using an Er: YAG laser (2,940 nm) and a special treatment head SMA. In essence this method takes advantage of the radiation of an erbium laser with a wavelength of 2,940 nm, which is well absorbed by water and is space modulated in such a way that an energy flux is applied to the treated surface with an ordered alternation between the maxima and minima the density of the energy (Alcolea et al., 2017; Hersant, SidAhmed-Mezi, Chossat, & Meningaud, 2017; Trelles & Khomchenko, 2019; Trelles, Khomchenko, Alcolea, & Martinez-Carpio, 2016; Volkova, Glazkova, Khomchenko, & Sadick, 2017; Volkova, Valamina, Shvidun, Rebrueva, & Sadick, 2019). The energy emitted in pulses, when interacting with the tissue modulates spatially which means that the energy affects not only the skin's surface, but also penetrates toward the inside of the dermis. This is achieved with the help of a special treatment head SMA that is 5 mm in diameter. It consists of a lens system that redistributes the energy flux, concentrates it in a spot, and creates zones with minimum and maximum degrees of effect that are 50 µm in size and that alternate with each other (Figure 1). In areas with a maximum degree of radiation, local areas of fine ablation are formed whose depth does not exceed the thickness of the epidermal layer. These areas of microablation are a source of acoustic waves. A mechanical wave is generated by the instant evaporation of the epidermal tissues accompanied by the progressive expansion of their volume and a sharp increase in pressure. Powerful acoustic resonance waves are transmitted into deeper tissues. The power of each of these waves emanating from the areas of microablation is not sufficient to destroy cells at the level



**FIGURE 1** Stain on photographic paper when exposed to SMA (magnified 10 times)

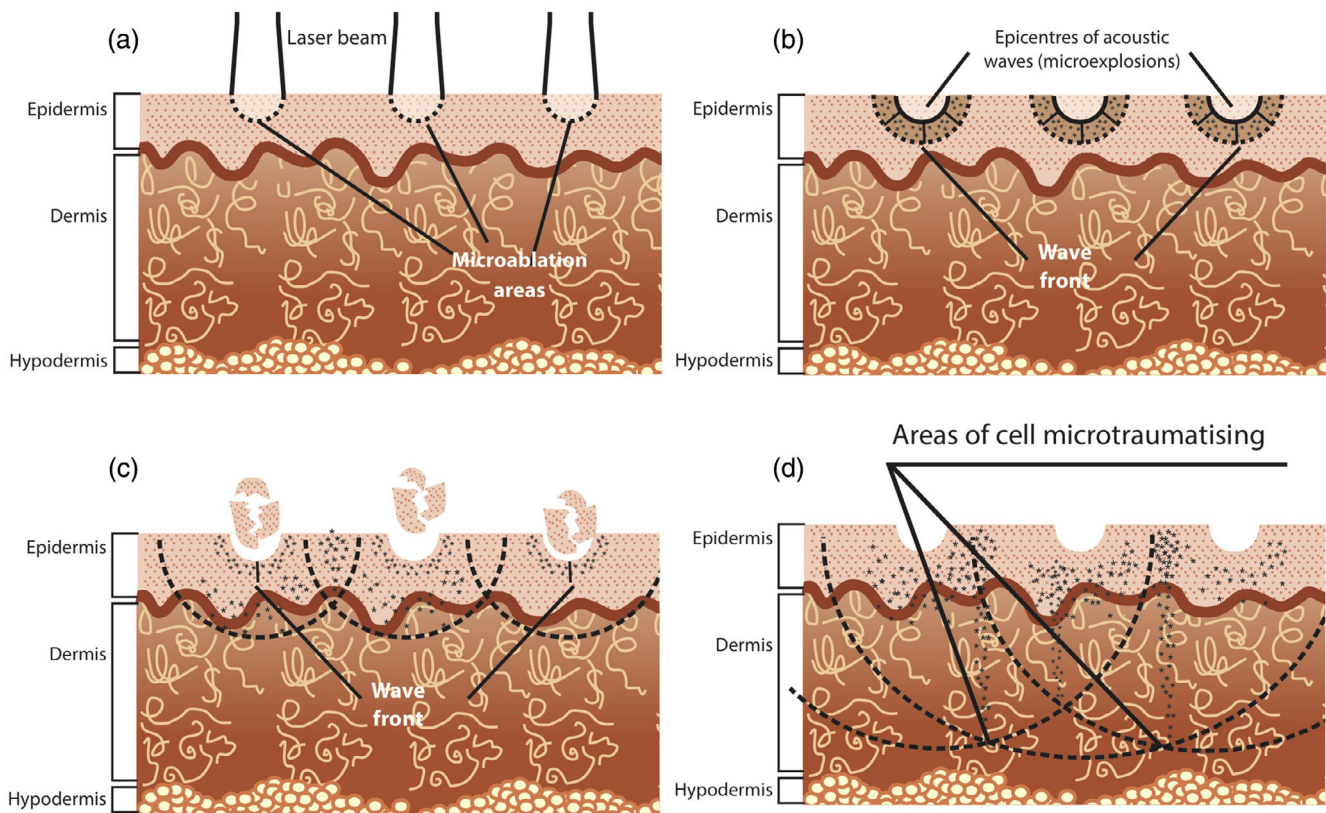
of the epidermis and basal membrane. However, due to diffusion in tissues at the level of the dermis, sound waves coming from neighboring areas experience interference. The intercrossing of the wave interference amplifies the resonance phenomenon, increasing the power acting on the tissue. This is able to cause damage to the cellular membranes, the cytoplasm and/or the nucleus and interfibrillar rupture of fibers through a mechanical action. As a result, microregions with mechanically destroyed cells and intercellular fibers surrounded by intact cells are formed at the level of the dermis (Trelles & Khomchenko, 2019; Volkova et al., 2019; Figure 2).

The changes that then occur in tissues have their own distinctive features: the laser energy propagates through the displacement of mechanical-acoustic waves which collide with each other while penetrating the skin, causing a gelification phenomenon of the dermis. The observed histological image is due to the lack of definition of dermic fibers, known as hyalinisation. Interfibrillar spaces increase due to the influence of the mechanical energy of waves, which causes the fibers to repel each other (Trelles & Khomchenko, 2019; Volkova et al., 2019).

Considering the way in which radiation is applied, the low degree of trauma produced by RecoSMA, and the fact that it does not produce a wounded area in the treatment zone, the absence of thermal damage the probability of side effects and the development of complications should be significantly lower than for the light and laser methods of treatment of psoriasis vulgaris that were discussed above. There is no risk of burns and scarring. Dyspigmentation may occur due to inflammatory process and not due to direct damage to the skin's melanin.

## 2.7 | Objective and subjective assessment of results

The clinical effectiveness of laser therapy using the RecoSMA technology was evaluated by studying how the values of the PASI and DLQI changed over the course of the treatment.



**FIGURE 2** Diagram illustrating how the SMA mechanism works: (a) Sites of microablation at the level of the epidermis; (b) Generation of acoustic waves; (c) Interference by waves coming from neighboring areas; (d) Areas of mechanical microtrauma at the level of the dermis (Alora et al., 1998)

The PASI is an objective indicator reflecting the severity of the patient's psoriasis, and it is a highly valid tool for evaluating the effectiveness of the course of treatment. The standardized PASI indicators were calculated before the start of treatment, before each subsequent treatment session, and at the end of the course of treatment. The amount of time to achieve clinical remission and the completeness of it was assessed used by the stratified regression indicators of PASI (Finlay, 2015; Richards et al., 2004).

The treatment effectiveness was assessed as follows in accordance with how the PASI changed:

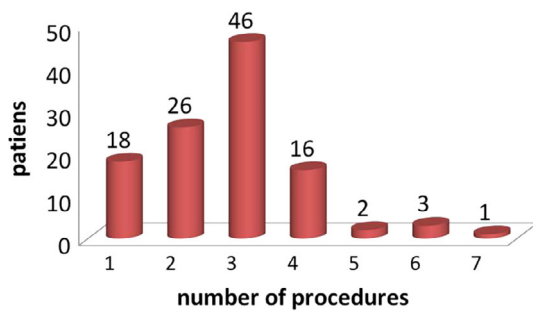
- Clinical remission: 95% or greater reduction in the index
- Significant improvement: a 94–75% decline in the index
- Improvement: a 74–50% decrease in the index
- No effect: a 50% or smaller decrease in the index
- Deterioration: an increase in the PASI.

A calculation of PASI and a visual analysis of the photographs before and at the end of treatment was carried out by an independent doctor, an expert in treating psoriasis.

The DLQI presents an integral picture of the physical, psychological, and emotional state according to the subjective estimation of the patient with psoriasis. DLQI data were obtained from patient-completed questionnaires. An analysis of the answers shows that psoriasis patients suffer from anxiety, depression, irritability due to the disease, isolation and lack of social opportunities, personal problems (creating a family, having a sex life), and social problems (securing employment, playing sports, etc.; Finlay, 2015; Griffiths & Barker, 2007; Richards et al., 2004). Improving the quality of life is the main goal of treating patients with a chronic illness like psoriasis. It is possible to evaluate the effectiveness of therapy and the patient's compliance by measuring how the DLQI indicator changes.

## 2.8 | Histological studies

Twelve patients in the study were randomly selected for biopsies before beginning the first treatment at 1 and 3 weeks after first session RecoSMA and after the entire course of treatment. Tissue samples were taken using infiltration anesthesia (Lidocaine 1% injectable solution) and were stained with hematoxylin/eosin (HE/EO). The



**FIGURE 3** Distribution of patients by number of SMA sessions during the course of treatment

analysis of samples was carried out by the Pathology Service of the Municipal Clinical Hospital (Voronezh, Russia).

### 3 | RESULTS AND DISCUSSION

Patients showed good tolerance for the procedure. The recovery period was characterized by the following features: a white dense frost appeared in the treated area after the laser treatment; a moderate burning feeling lasted for 1 hr; a dense crust formed in the treatment area a day later; on the fifth through seventh day after the completed session, peeling in the lesion area become more pronounced and persisted with a tendency to subside within 1–3 days. Then the lesion cleared up. The positive clinical effect became noticeable 2 weeks after the session. It manifested itself in less severe symptoms (reduced erythema, infiltration, and peeling) and a shrinking lesion area.

Patients did not have to make any modifications to their habitual lifestyle. There were no side effects or complications in the study group.

After the first session, the majority of patients reported a significant reduction in the number of clinical symptoms (infiltration, hyperemia, and peeling) and the size of the lesion area.

The average number of procedures in the study group was 2.7 ( $r = 1-7$ ). The distribution of patients by the number of performed procedures during the course of treatment is shown in the diagram (Figure 3).

At the end of the course of treatment, the mean PASI score was  $1.1 \pm 0.08$  points ( $p = .002$ ). These parameters were statistically significant ( $p = .002$ ). It had decreased by 7.6 times or 86.9% from the pre-treatment score. (Table 1).

During the course of treatment, as the patients' clinical findings improved, their DLQI quality of life indicators also improved proportionally. Thus, after the course of treatment by space modulated ablation, the mean indicator was  $2.21 \pm 0.9$  points ( $p = .003$ ), which corresponds to an improvement of 3.6 times or 72% ( $p = .004$ ) in comparison with the initial value (Figure 4).

As a result of laser therapy using the Er:YAG laser with the RecoSMA technology, 98 (87.5%) patients achieved clinical remission, 11 (9.8%) patients showed significant improvement,

**TABLE 1** Changes in the mean values of the PASI and DLQI indexes

Indicator	Initially	After the course of treatment	P
PASI, points ( $n = 112$ )	8.4	1.1	0.002
DLQI, points ( $n = 112$ )	7.9	2.21	0.003
PASI, %	100	86.9	0.002
DLQI, %	100	72	0.004

Note: The average values of the indicators are given.  
Abbreviations: N, number of patients; P, Wilcoxon index.

and 2 (1.8%) patients showed improvement. Only one patient (0.9%) did not benefit from the treatment (that patient's PASI score did not change significantly and amounted to less than 50%). No one in the study experienced any worsening symptoms (Figure 5).

#### 3.1 | Histological studies

Changes in the samples from psoriatic plaques was similar in all 12 patients who took a biopsy. The samples before beginning the treatment presented multilayer flat epithelium tissue with uneven thickness, including thinning of and in some places disappearance of the granular layer. There was wide area affected by parakeratosis and hyperkeratosis. In the stromal papillae there are dilated capillaries with edematous walls and inflammatory infiltration.

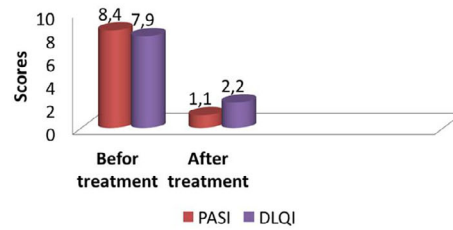
In samples taken after 1 week first session of RecoSMA, an accumulation of neutrophilic leukocytes in the parakeratotic layer (cymptommm Munro) was noticed.

There was epidermis with long acantholytic growths that have developed anastomoses between each other and are extending downward. The parakeratosis zone was not prominent. There was a narrow granular layer. The stromal papillae were swollen, with inflammatory infiltration around the capillaries. The dermal lesion showed evidence of inflammatory infiltration mainly around the vessels. The infiltration consisted mainly of mononuclear cells with an admixture of neutrophilic leukocytes. In the area of the apex of the stromal papillae the epidermis had thinned to several cell layers.

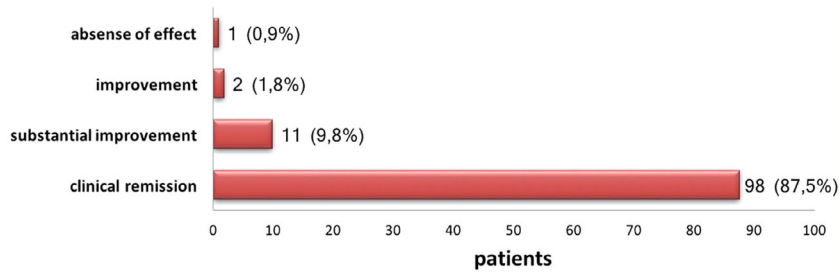
In samples taken after 3 weeks first session of RecoSMA, the epidermis had a narrow layer of parakeratosis and hyperkeratosis with small acantholytic growths. There was practically no inflammatory infiltration around the capillaries in the stromal papillae.

After the completion of the course of RecoSMA treatment the skin had an almost normal structure with a narrow layer of parakeratosis and hyperkeratosis. A granular layer was present. The stromal papillae was without edema. Single inflammatory infiltration could be found around the vessels (rare inflammatory infiltration could be seen when examining the specimen; Figure 6).

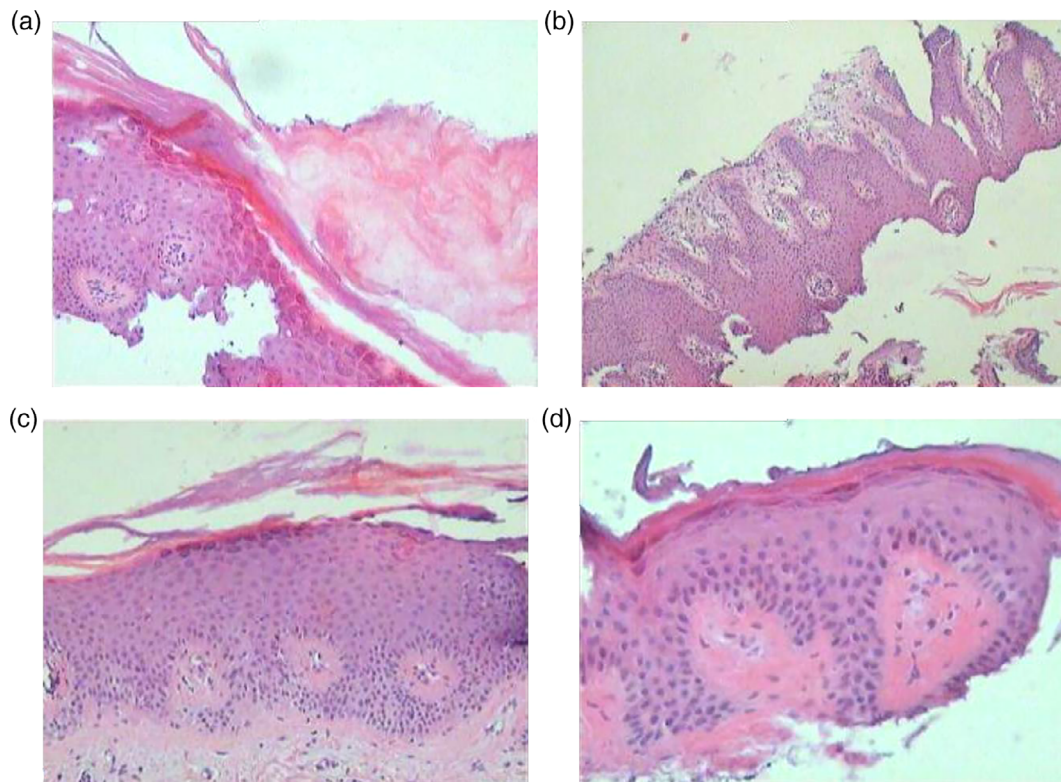
Indicator	Initially	After the course of treatment	p
PASI, points (n= 112)	8.4	1.1	0.002
DLQI, points (n= 112)	7.9	2.21	0.003
PASI, %	100	86.9	0.002
DLQI, %	100	72	0.004



**FIGURE 4** Changes in the mean values of the PASI and DLQI indexes in response to the SMA method laser treatment



**FIGURE 5** Clinical effectiveness of the method of space modulated ablation



**FIGURE 6** Histological study of the lesion (hematoxylin and eosin stain): (a) Before starting the treatment sessions. (b) 1 week after the first RecoSMA session. (c) 3 weeks after the first RecoSMA session. (d) After the completion of the course of RecoSMA treatment

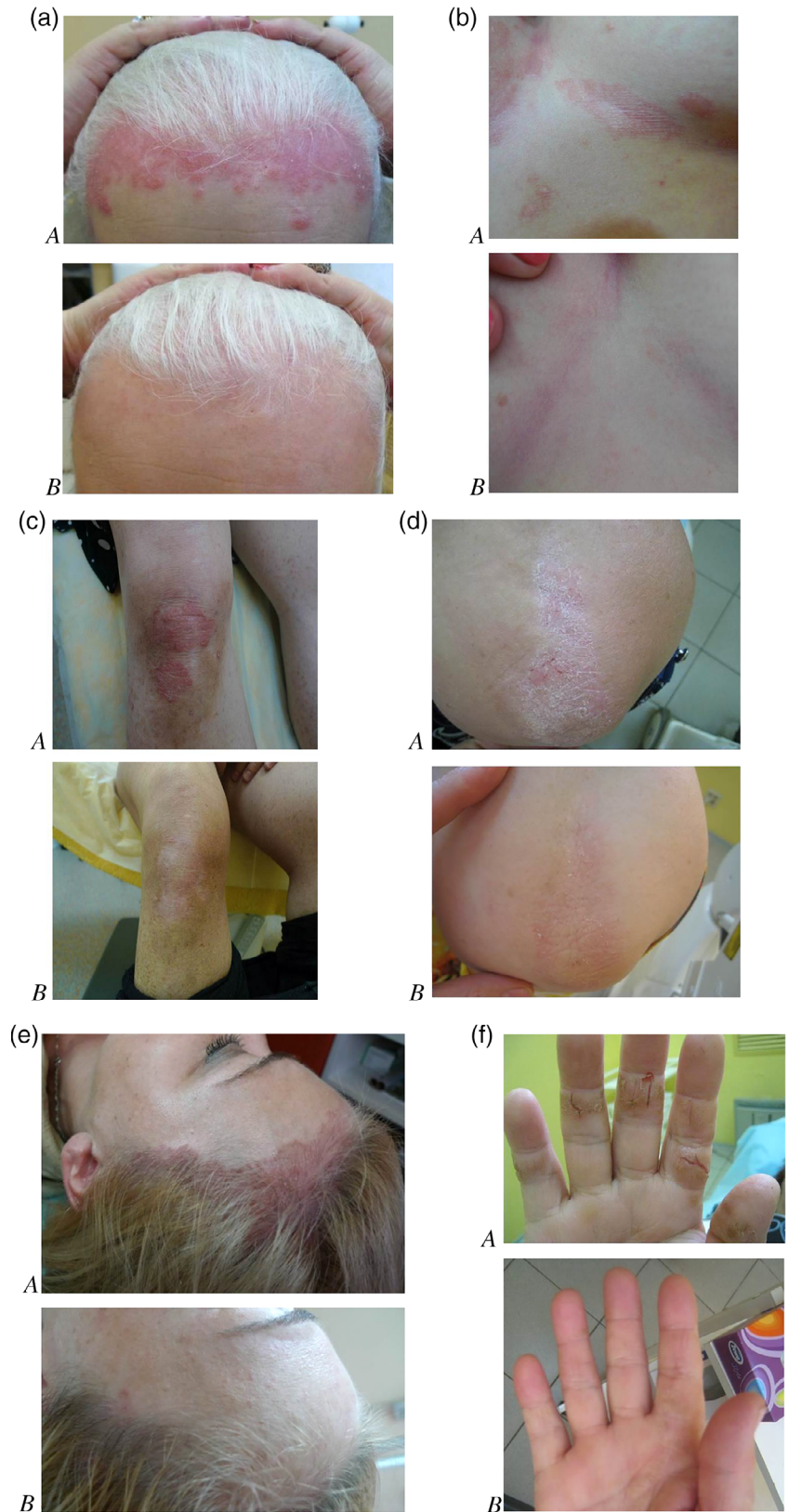
The results of the treatment (clinical examples) of psoriasis on different parts of the bodies of patients are presented in photographs taken before and after the procedures (Figure 7).

At the time of writing, of those remaining members (14) of the study group under supervision 8 patients have reported that their psoriasis symptoms have remained in remission since the course of

treatment. Thus, the remission has already lasted 4 years. The observation period continues in order to determine the maximum period.

Thus, the RecoSMA technology has proven itself to be highly effective for the treatment of skin manifestations of psoriasis vulgaris as a monotherapy. We did not observe a correlation between the length of the disease and the achieved results of treatment. The

**FIGURE 7** (a) Patient B. 38 years old: A, before treatment; B, after two SMA sessions. (b) Patient D. 42 years old: A, before treatment; B, after one SMA session. (c) Patient P. 52 years old: A, before treatment; B, after three SMA sessions. (d) Patient A. 48 years old: A, before treatment; B, after two SMA sessions. (e) Patient B. 35 years old: A, before treatment; B, after six SMA sessions. (f) Patient S. 34 years old: A, before treatment; B, after two SMA sessions



absence of significant changes in the psoriatic process in one patient can most likely be explained by the polysystemic nature of the disease. In light of this observation, most researchers consider the use of combined treatment regimens to be the most promising (Lowes &

Young, 2010; Reich & Bewley, 2011). Often laboratory and instrumental examinations of patients with psoriasis reveal latent systemic disorders that affect the functioning of the skin and may be the cause of unsatisfactory results of external therapy. Comprehensive

examinations of patients with psoriasis before the start of treatment that aim to identify hidden pathologies in need of treatment in combination with the laser method of treating cutaneous manifestations will presumably make the procedure even more effective while minimizing the percentage of cases that derive no benefit from the therapy. An extensive study is needed to confirm this hypothesis.

Outside the study group, an additional five patients with palmar-plantar psoriasis were treated using the Er:YAG laser with the RecoSMA technology. A significant improvement was observed in all patients. Four patients achieved complete remission of psoriasis. It is still too early to speak about whether the RecoSMA is effective for treating this form of psoriasis due to the small number of observations. However, over the long term we suspect that the indications for the application of this method to treat this pathology will increase.

## 4 | CONCLUSIONS

The results of the clinical trial confirm the effectiveness of RecoSMA technology for the treatment of skin manifestations of psoriasis vulgaris that are progressing slowly and stably, and they demonstrate an improvement in the quality of life of patients after the course of treatment. According to the protocol used, skin pathological process has reached complete remission in 87.5% of patients and a significant improvement in 9.8%. The length of remission of the patients' psoriasis reaches 4 years at the moment, which is comparable to results achieved by alternative methods of psoriasis laser treatment. The course of psoriasis laser therapy using the RecoSMA is characterized by large intervals between procedures and the lack of onerous restrictions placed on patient lifestyles after the treatment, which ensures a high compliance rate by patients. Laser treatment is simple to carry out and there is no risk of morbidity, given that no complications were observed during the entire time of this study. The use of RecoSMA to treat psoriasis requires further study to determine the maximum duration of remission of the psoriasis condition, the effectiveness of the method when applied in combined treatment regimens, and the possible expansion of the indications for its use.

### ORCID

Torello Lotti  <https://orcid.org/0000-0003-0840-1936>

Mohammad Jafferany  <https://orcid.org/0000-0001-6358-9068>

### REFERENCES

- Alcolea, J. M., Hernández, E., Martínez-Carpio, P. A., Vélez, M., Khomchenko, V., Sola, A., & Trelles, M. A. (2017). Treatment of chronic lower extremity ulcers with a new Er:Yag laser technology. *Laser Therapy*, 23(6), 211–222.
- Alora, M. B. T., Anderson, R. R., Quinn, T. R., & Taylor, C. R. (1998). CO<sub>2</sub> laser resurfacing of psoriatic plaques: A pilot study. *Lasers in Surgery and Medicine*, 22(3), 165–170.
- Bekassy, Z., & Astedt, B. (1986). Carbon dioxide laser vaporization of plaque psoriasis. *British Journal of Dermatology*, 114(4), 489–492.
- Damevska, K., França, K., Lotti, T., Nikolovska, S., & Pollozhani, N. (2018). Complementary and integrative therapies for psoriasis: Looking forward. *Dermatologic Therapy*, 31, e12627. <https://doi.org/10.1111/dth.12627>
- Drew, G. S. (2000). Psoriasis. *Primitive Care*, 23(2), 385–406.
- Finlay, A. Y. (2015). Patient-reported outcome measures in psoriasis: Assessing the assessments. *The British Journal of Dermatology*, 172, 1178–1179.
- Griffiths, C. E., & Barker, J. N. (2007). Pathogenesis and clinical features of psoriasis. *Lancet*, 370, 263–271.
- Hersant, B., SidAhmed-Mezi, M., Chossat, A., & Meningaud, J. P. (2017). Multifractional microablative laser combined with spatially modulated ablative (SMA) technology for facial skin rejuvenation. *Lasers in Surgery and Medicine*, 49(1), 78–83.
- Lowes, M. A., Bowcock, A. M., & Krueger, J. G. (2007). Pathogenesis and therapy of psoriasis. *Nature*, 445, 866–873.
- Lowes, P. M., & Young, H. S. (2010). Topical treatment of psoriasis. *Expert Opinion on Pharmacotherapy*, 11(12), 1999–2009.
- Rapp, S. R., Feldman, S. R., Exum, M. L., Fleischer, A. B., Jr., & Reboussin, D. M. (1999). Psoriasis causes as much disability as other major medical diseases. *Journal of the American Academy of Dermatology*, 41(3 Pt 1), 401–407.
- Reich, K., & Bewley, A. (2011). What is new in topical therapy for psoriasis? *Journal of the European Academy of Dermatology and Venereology*, 25(Suppl. 4), 15–20.
- Richards, H. L., Fortune, D. G., Weidmann, A., Sweeney, S. K. T., & Griffiths, C. E. M. (2004). Detection of psychological distress in patients with psoriasis: Low consensus between dermatologist and patient. *British Journal of Dermatology*, 151, 1227–1233.
- Trelles, M. A., & Khomchenko, V. (2019). Reflections on the Er:YAG laser used in “nonthermal mode” to rejuvenate skin. *Photobiomodulation, Photomedicine, and Laser Surgery*, 37(9), 515–516.
- Trelles, M. A., Khomchenko, V., Alcolea, J. M., & Martínez-Carpio, P. A. (2016). A novel method of facial rejuvenation using a 2940-nm erbium:YAG laser with spatially modulated ablation: A pilot study. *Lasers in Medical Science*, 31(7), 1465–1471.
- Volkova, N. V., Glazkova, L. K., Khomchenko, V. V., & Sadick, N. S. (2017). Novel method for facial rejuvenation using Er:YAG laser equipped with a spatially modulated ablation module: An open prospective uncontrolled cohort study. *Journal of Cosmetic and Laser Therapy*, 19(1), 25–29.
- Volkova, N. V., Valamina, I. E., Shvidun, D. V., Rebreva, A. S., & Sadick, N. S. (2019). Facial rejuvenation using Er:YAG laser equipped with a spatially modulated ablation module: A clinical, ultrasound, and histological evaluation. *Journal of Cosmetic Dermatology*, 00, 1–6.
- Zhang, P., & Wu, M. X. (2017). A clinical review of phototherapy for psoriasis. *Lasers in Medical Science*, 33(1), 173–180.

**How to cite this article:** Kalashnikova NG, Lotti T, Urakova DS, Jafferany M. Treatment of psoriatic skin lesions with a new Er:Yag laser technology: A case series study. *Dermatologic Therapy*. 2020:e13264. <https://doi.org/10.1111/dth.13264>